



Exophthalmia in wild-caught cod (*Gadus morhua* L.): development of a secondary barotrauma effect in captivity

O-B Humborstad¹, K Ferter^{1,2}, H Kryvi² and P G Fjelldal³

¹ Institute of Marine Research, Bergen, Norway

² Department of Biology, University of Bergen, Bergen, Norway

³ Matre Research Station, Institute of Marine Research, Matredal, Norway

Abstract

Capture-based aquaculture (CBA) of Atlantic cod (*Gadus morhua*) has become increasingly important in recent years, and increased attention is being paid to animal welfare issues linked to these activities. Earlier studies showed that some cod develop secondary exophthalmia in captivity. This study investigated the development of secondary exophthalmia in two groups of wild-caught cod, one of which was exposed to rapid decompression causing acute barotrauma (treatment group) while the other was not (control group). Photographs and radiographs before and up to 33 days after barotrauma revealed a significant increase in overall eye protrusion caused by an accumulation of gas in the orbita in the treatment group, first observed on day 9 after decompression, while no protrusions were observed in the control group. Barotrauma was thus identified as an important trigger for the development of secondary uni- or bilateral exophthalmia of wild-caught cod. Two underlying mechanisms are suggested, where the more likely is residual swim bladder gas taking the route of least resistance, while the less likely is the exsolution of gas from the blood. Our results have implications for a wide range of contexts in which cod are rapidly brought to the surface from great depth.

Keywords: barotrauma, decompression, exophthalmia, fish welfare, swim bladder puncture.

Introduction

Atlantic cod (*Gadus morhua*, hereinafter: cod) is a commercially important species that inhabits shallow surface waters as well as depths down to more than 500 m (Bergstad 1991). In Norway, live cod captured by demersal seine are put into capture-based aquaculture (CBA) to supply markets with fish throughout the year and increase the value of catches (Ottolenghi *et al.* 2004; Midling *et al.* 2012;). On a smaller scale, cod are captured with static gear (pots, traps and trammel nets) and kept in tanks at fish markets for direct sale.

Keeping cod in tanks can lead to a high incidence of eye lesions (Moran, Tubbs & Støttrup 2012; and references therein). One of the most frequent changes in the eye is exophthalmia [eye protruding from orbit (Hannah *et al.* 2008a), also termed 'popeye' (Dukes 1975; Moran *et al.* 2012)]. In 1966, Dehadrai (1966) stated that wild-caught cod held in captivity often develop exophthalmia, which made them useless for many experimental studies. Exophthalmia can be acute or may develop gradually over time. However, the aetiology of the condition, which may be due to infections, holding conditions or mechanical injury, is not well understood (Dukes 1975; Moran *et al.* 2012).

Acute exophthalmia is frequently observed during fishing and especially amongst physoclistous species which suffer from barotrauma (Parrish & Moffitt 1992; Rummer & Bennett 2005; Hannah *et al.* 2008a; Hannah, Parker & Matteson 2008b; Ferter *et al.* 2015). Swim bladder rupture is commonly observed [e.g. the swim bladder of cod punctures at approximately 70% pressure reduction relative to acclimation depth (i.e. from 23 m to

Correspondence O-B Humborstad, Institute of Marine Research, NO 5817 Bergen, Norway (e-mail: oddb@imr.no)

0 m) (Tytler & Blaxter 1973)]. Exophthalmia as a result of exsolution of gas from supersaturated blood and tissues (Henry's law) or due to expanding gas from a ruptured swim bladder following the path of least resistance within the body (Parker *et al.* 2006; Hannah *et al.* 2008a; Boyle's law, Brown *et al.* 2012) is also common. Acute exophthalmia due to unfavourable holding conditions has been reported to occur in juvenile cod kept in nitrogen-supersaturated water (Gunnarsli, Toften & Mortensen 2008) and during chronic CO₂ exposure (Moran *et al.* 2012). Stephens *et al.* (2001) found that excessive exercise and/or high water temperature may be important risk factors for the development of exophthalmia in West Australian dhufish *Glaucosoma hebraicum* Richardson.

Dehadrai (1966) observed that 70% of trawl-caught cod gradually developed secondary uni- and bilateral exophthalmia within 7 days after capture when kept in the laboratory. As these fish were probably caught in deeper waters (although capture depth was not reported) and the exophthalmic fish were floating belly-up (which is a known acute barotrauma sign), barotrauma could be the predisposing stimuli, as also suggested by Dukes (1975). Dehadrai (1966) prevented secondary exophthalmia by removal of the pseudobranch or injection of a carbonic anhydrase inhibitor and concluded that exophthalmia seemed to be a malfunctioning of the choroid gland–pseudobranch complex triggered by unknown stimuli.

Acute and secondary exophthalmia can, amongst other effects, lead to stretching/parting of the optic nerve, vision/behavioural impairment, haemorrhaging and blindness (Dukes 1975; Grahn *et al.* 2007; Hannah & Matteson 2007; Rogers *et al.* 2008). Given the growing importance of capture-based cod aquaculture, and concurrent welfare issues (Humborstad & Mangor-Jensen 2013), it is important to find out how the development of secondary barotrauma in cod is triggered and what the underlying mechanism might be. Thus, the aim of this study was to investigate whether barotrauma may lead to the development of secondary exophthalmia in wild-caught cod held in captivity.

Material and methods

We studied the development of secondary exophthalmia (morphometrics on photographs, head radiography) and other eye injuries (external pathology) in cod. For this purpose, triplicate

groups of cod were submerged to 40 m (induced barotrauma treatment group) and 5 m (control group) depth for 9 days, and then rapidly decompressed to the surface where they were kept for 33 days in an indoor tank to study the development of secondary exophthalmia over time.

Fish stock

Eighteen wild cod (34–75 cm; mean 49.8 cm) were caught in fyke nets deployed at depths of between 3 and 7 m in Masfjorden (Western Norway) in February 2014. Total length and weight were measured for individual fish to the nearest lower cm or g respectively, examined for eye pathologies to ensure that their eyes were free of injuries or visible abnormalities at the onset of the experiment, and tagged by means of a hollow-needle tagging-gun and individually numbered T-bar anchor tags (TBA-1; Hallprint Pty. Ltd.), inserted on the left of the fish in front of the first dorsal fin engaging the dorsal pterygiophores. All fish were measured, photographed, radiographed, tagged and examined under anaesthesia with Finquel MS222 (0.15 g L⁻¹, Argent Chemical Laboratories Inc.).

Experimental set-up

After the first photography and radiography immediately after capture, the fish were randomly distributed between six identical cages, with three fish per cage (Table 1). Each cage consisted of three polyethylene rings (90 cm diameter) covered with black 28-mm mesh opening (stretched mesh) net twine. The total height of the cages was 2 m, and the lowest ring was weighted for stability. The six cages were randomly assigned to two groups of three cages. One group was lowered (~10 m min⁻¹) to a depth of 40 m (treatment group) and the other to 5 m (control group) at the Institute of Marine Research's (IMR) sea farm Smørdalen, Matre, Norway (day -9). The size ranges were 38–72 cm (mean 51.3 cm) and 34–75 cm (mean 41.3 cm) in the control and in the treatment groups, respectively.

After 9 days, the cages were hauled to the surface (~10 m min⁻¹), and the fish were brought ashore for photography, radiography, examination of eye pathologies and buoyancy determination (floating/diving) (day 0). Radiography and imaging was started approximately one hour post-surfacing. The fish were then transferred to an indoor

Table 1 Descriptive statistics. Gonadal status: mature (M)/immature (IM), sex: male (M)/female (F), gas release: gas release observed as gas bubbles in the water on decompression from deep water on day 0, buoyancy day 0: diving (D), floating (F) on day 0, gas channel day 0: gas-filled channel present (Yes) or not present (No) as observed on radiographs on day 0, exophthalmia day 33: exophthalmia present (Left, Right or Both) or not present (No) as observed on photographs on day 33.

Acclimation depth	Fish number	Cage	Total length (cm)	Weight (g)	Gonadal status	Sex	Survival	Gas release	Buoyancy day 0	Gas channel day 0	Exophthalmia day 33
5 m	1	1	72	3886	M	F	Yes	No	D	No	No
	2	1	62	2222	M	F	Yes	No	D	No	No
	3	1	39	543	IM	F	Yes	No	D	No	No
	4	2	42	715	IM	M	Yes	No	D	No	No
	5	2	49	1241	IM	M	Yes	No	D	No	No
	6	2	53	1691	M	M	Yes	No	D	No	No
	7	3	38	465	IM	M	Yes	No	D	No	No
	8	3	45	922	IM	F	Yes	No	D	No	No
	9	3	62	2829	M	M	Yes	No	D	No	No
40 m	10	4	36	507	IM	M	Yes	Yes	D	No	Left
	11	4	36	434	IM	M	Yes	Yes	D	No	Right
	12	4	55	2122	na	na	No	Yes	D	Yes	na
	13	5	75	3810	M	F	Yes	Yes	F	No	No*
	14	5	38	515	na	na	No**	Yes	F	Yes	na
	15	5	40	590	IM	M	Yes	Yes	F	Yes	Both
	16	6	60	2105	M	F	No	Yes	F	Yes	na
	17	6	61	2240	M	F	Yes	Yes	D	No	No
	18	6	34	360	IM	F	Yes	Yes	F	No	Both

*Developed severe eye damage (see text for details).

**Eaten.

500-L green fibreglass tank supplied with flow-through sea water at a temperature at 8.9 °C and oxygen saturation below 100%, in order to avoid exophthalmia caused by supersaturation.

The fish were photographed, radiographed and examined for eye pathologies 9, 21 and 33 days after the decompression day. At the terminal examination on day 33, the fish were killed by an overdose of anaesthetics (400 mg L⁻¹, Fiquel MS222). After photography and radiography, gas accumulation was investigated by submerging them in water and inserting a hollow needle behind the eye cavity for visual inspection of bubbles. Fish were then dissected within two hours post-euthanasia and determined for sex, maturity status and swim bladder pathologies.

Photography

In order to quantify external signs and development of exophthalmia, high-resolution (350 dpi) digital jpg photographs were taken viewing dorsally towards the head region, against a white paper background, using a Sony alpha77 camera (Sony Corporation) with a Sigma electronic macro flash (EM-140 DG; Sigma Corporation) attached. The distance between the fish head and the camera was ~70 cm, depending on fish height.

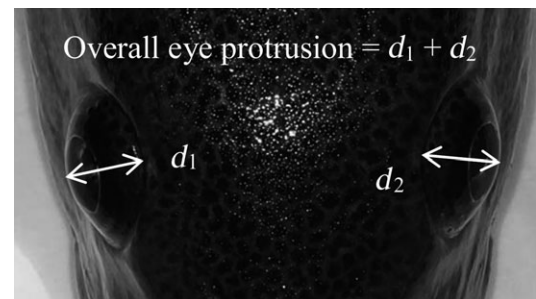


Figure 1 Dorsal view of cod during photography under anaesthesia. Eye protrusion was measured as the distance from the edge of the eye cavity to the point on the edge of the cornea dividing the visible eye area into symmetrical mirror halves.

Exophthalmia was determined by visual inspection, and its magnitude was quantified by measurements on photographs. The distance from the border of the eye cavity to the point on the edge of the cornea that divided the visible eye area into symmetric mirror halves (Fig. 1) was measured using the measurement tool of the ImageJ software (U.S. National Institutes of Health). Measurements were calibrated against a known scale to the closest tenth of a millimetre. For every individual and point in time, each eye was measured 10 times and the overall eye protrusion was calculated as the sum of the two medians. Median (rather than

mean) was used as a measure because some outliers were observed on consecutive measurements. Overall, eye protrusion was used in the analysis because minute differences in fish placement (causing minute differences in the sagittal plane angle) for photography occurred on consecutive fish measurements, and the sum of eye protrusion, rather than single eye measurements, was consistent with visual observations. In order to allow for statistical comparison between treatment groups, the relative eye protrusion was calculated for each sampling day and treatment group as the mean overall eye protrusion on the respective sampling day divided by the mean overall eye protrusion at the start of the experiment (day -9). Relative eye protrusion was compared between groups (control/treatment) and across sampling days using the Kruskal–Wallis rank sum test for multiple comparisons (kruskalmc from R-package pgirmess, R version 2.15.3, R Core Team, 2013). Significance was accepted at $\alpha = 0.05$.

Radiography

In order to inspect the fish for internal gas accumulation (present/absent) in the eye region, lateral and dorsal radiographs were taken of the region covering the head and the trunk using a portable X-ray apparatus (Porta 100 HF; Eickemeyer Medizintechnik für Tierärzte KG) onto a 35×43 cm image plate in a rigid cassette (Dürr Medical; Bietigheim-Bissingen) with 40–50 kV (depending on fish size) and 10 mAs at a distance of 70 cm. The image plate was scanned (CR 35 VET; Dürr Medical) and the resulting image converted into a TIFF file (Vet-Exam Plus Software, version 4.14.0). The software program Adobe Photoshop CS2 was used to detect any accumulation of gas within the head.

The study complies with the Norwegian regulations on animal experimentation. Experiments were approved by the animal experimentation committee (approval ID 5796) of the Norwegian Animal Research Authority.

Results

Swim bladder pathologies

During forced decompression (day 0), all the fish from the treatment group were observed to release gas from the anal area at about three to five m

below the surface (Table 1), which is a clear indication of swim bladder rupture. Five fish from the treatment group were positively buoyant, floating (belly-up and/or sideways), or partly floating and attempting to dive during transport to the laboratory. One of these floating fish (Table 1, fish no. 13) did not manage to dive after transfer to the tank and remained positively buoyant floating/swimming belly-up for the rest of the experiment. This fish also had gas in the abdominal cavity, clearly seen from radiographs. The remaining fish rapidly recovered (within 24 h) and managed to control their behaviour, with no apparent buoyancy challenges for the rest of the experiment. Radiographs confirmed gas accumulation outside the swim bladder after forced decompression (day 0, Table 1) in all fish from the treatment group. The gas was observed surrounding the posterior part of the swim bladder with an exit pathway around the anus. This is consistent with earlier findings on swim bladder puncture (Ferber *et al.* 2015), where the gas is present between the peritoneum and the swim bladder, and not in the abdominal cavity (except fish no. 13). This gas accumulation gradually diminished and was not detectable on the day of termination of the experiment. A gas-filled channel above the spinal cord spanning from the head to the tail was observed in four cod from the treatment group immediately after forced decompression (day 0, Table 1), but was not observed on later radiographs. At termination (day 33), post-mortem dissections of the fish revealed that the swim bladders were filled and were of normal appearance in all fish. In the treatment group, post-mortem dissection revealed sealed holes in the swim bladders of all fish, except fish no. 17 (Table 1). The holes (one per fish) were located in the posterior region of the swim bladder, close to the edge where the bladder meets the muscle tissue and pinbone points. None of the fish from the control group were observed to release air during haul-up and their swim bladders appeared normal from radiographs and dissections.

Eye pathologies

On day -9, all the fish had normal eyes as evaluated by external appearance, photographs and radiographs (Fig. 2). None of the treatment or control fish showed exophthalmia on the decompression (day 0), nor was gas observed in or around the eye for any fish. Four fish from the treatment group

Figure 2 Development of unilateral (fish no. 11) and bilateral (fish no. 18) secondary exophthalmia in two cod that were submerged to 40 m between day -9 and day 0 and then kept in a seawater tank from day 0 to 33. Exophthalmia was clearly observed in the form of eye protrusion on photographs (white arrow heads). Gas accumulation present posterior to the eyeball was visible as concave and convex banana-shaped white areas on radiographs (black arrow heads) that caused the eye to bulge out of the orbit.

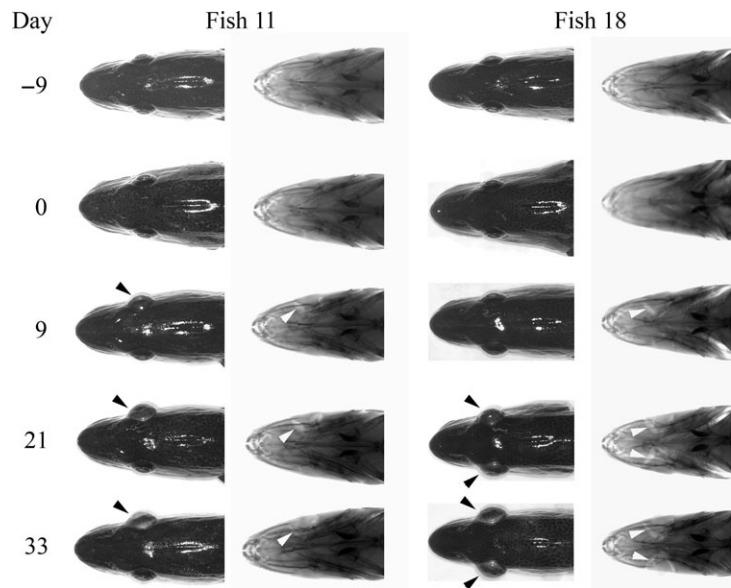
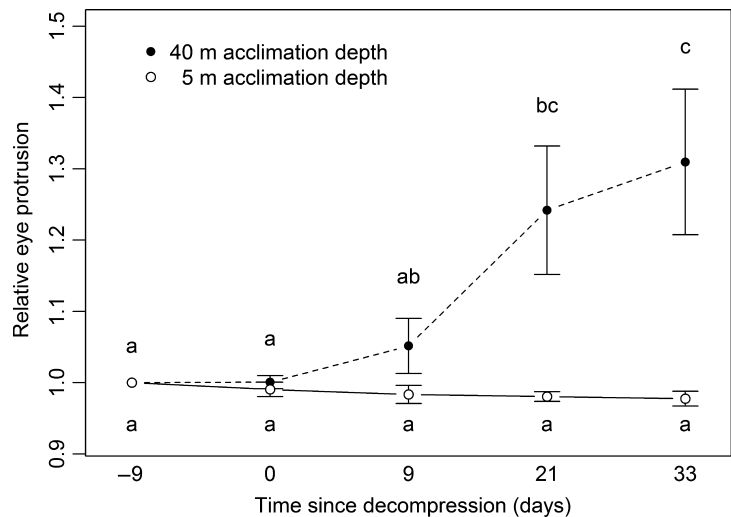


Figure 3 Development of mean overall eye protrusion (presented as relative eye protrusion) in the treatment and control groups. In the treatment group, cod were exposed to rapid decompression from acclimation at 40 m depth on day 0, and in the control group, cod were hauled up from acclimation at 5 m depth on day 0. Significant differences between groups of mean (\pm standard error) are indicated by different letters (a, b, c). Fish no. 13 was omitted due to severe external eye damage.



developed secondary exophthalmia during the course of the experiment; two unilateral, and two bilateral. Exophthalmia was first observed on day 9 (Fig. 2). Exophthalmia was observed both in the form of protruding eyes on photographs and as expanding white areas in the orbita on radiographs (Fig. 2). Significant differences in relative eye protrusion between the treatment and control group were evident from day 21 and onwards (Fig. 3). A significant change in relative eye protrusion with time was observed in the treatment group, but not in the control group.

Fish no. 13 showed a noticeable decrease in eye protrusion at day 0, an abrasion above the right

eye on day 9, opaque cornea and sunken right eyeball on day 21, and absence of the right eyeball at termination (day 33). On day 33, buphthalmos (enlargement of the eye) was observed in fish no. 15, which also had clinical manifestations of ocular emphysema (gas in the eye) in addition to exophthalmia (Fig. 4).

Mortality

Three fish died during the course of the experiment (Table 1), one of them (no. 16) within one hour after decompression from 40 m (day 0). Dissection of this fish immediately (less than one



Figure 4 Acute ocular emphysema (gas bubbles in the anterior chamber), exophthalmia (protruding eye), and probable buphthalmia (fluidal enlargement of the eyeball) in fish no. 15 on day 33.

hour) after its death revealed numerous and large bubbles in a number of blood vessels and organs including the heart, and severe bleedings/haemorrhages within the lumen of the swim bladder. Fish no. 12 died after 11 days in the tank. Post-mortem evaluation on the same day did not reveal any clear pathology. Fish no. 14 was eaten by fish no. 1 in the tank some time between day 9 and 21.

Discussion

While wild-captured fish may display a variety of acute barotrauma signs caused by rapid changes in hydrostatic pressure during ascent from deeper water (e.g. Rummer & Bennett 2005; Ferter *et al.* 2015), our study demonstrates that barotrauma also predisposes the development of secondary exophthalmia in wild-caught cod under laboratory conditions. Radiological examinations of individual fish over time identified progressive gas accumulation in the orbita as the cause of the eye protrusion (Fig. 2).

The most plausible explanation for secondary exophthalmia after barotrauma is that the gas originates from excess swim bladder gas moving inside the fish. In line with previous findings (Midling *et al.* 2012; Ferter *et al.* 2015), a substantial amount of gas was present surrounding the posterior part of the swim bladder with an

exit pathway around the anus upon surfacing, as was visible on the radiographs. If the swim bladder ruptures due to barotrauma, most of the gas is released from the fish body through a release mechanism for surplus gas (Midling *et al.* 2012; Ferter *et al.* 2015), after which healing takes place and gas secretion functions are rapidly regained. Midling *et al.* (2012) noted that gas was still present outside the swim bladder in four of 20 fish up to 16 days past puncture. Similarly, we observed both gas release and gas outside the posterior part of the swim bladder with an exit pathway around the anus, on radiographs in all of the fish in the treatment group. Further, both our study and the recent study by Ferter *et al.* (2015) showed that barotrauma induced a lateral gas-filled channel dorsal to the vertebral column, probably indicating the presence of gas in the *canalis vertebralis*. In the present study, this gas channel was only observed on radiographs on day 0, when the fish were brought up from 40 m and disappeared before the first visible signs of exophthalmia were observed, suggesting a potential movement of gas; however, only one fish had both pathological signs (Table 1). The three other fish (fish nos. 12, 14 and 16, Table 1) which had gas in the *canalis vertebralis* all died before day 21 when exophthalmia became most obvious (Fig. 3). Hannah *et al.* (2008a) presented data that suggested that the gross external signs of acute barotrauma in Pacific Rockfish (*Sebastes spp.*) primarily develop as a result of expanding swim bladder gases following the path of least resistance within the body and not from exsolution of gas from body fluids. Hannah *et al.* (2008a) found gas medially to the eyeball, between the globe and surrounding the orbital bones, that likely travelled anteriorly along the ventral surface of the skull and into the orbit. Similarly, Brown *et al.* (2012) concluded that the gas bubbles which Chinook salmon (*Oncorhynchus tshawytscha* W.) showed in the blood stream after rapid decompression originated from inside the swim bladder. Rogers *et al.* (2008) also concluded that acute exophthalmia in rockfish was caused by expanding swim bladder gas that ruptured the peritoneum and filled the orbital regions, forcing pressure to increase and pushing the eye out of its socket. Those results, together with the close proximity of the gas channel to the progressive exophthalmic gas accumulation, suggest that the origin of gas behind the eyes in our study may well be an accumulation of

swim bladder gas following the route of least resistance, as is the case of fish showing acute exophthalmia after rapid decompression, yet at a much slower progression.

The first occurrence of exophthalmia was observed 9 days after decompression (Fig. 2 and Fig. 3). Similarly, Dehadrai (1966) reported that secondary exophthalmia was visible 7 days after wild-caught cod were transferred to onshore tanks and concluded that this was attributable to a malfunctioning of the choroid gland–pseudobranch complex. However, there is no clear rationale to connect our path of least resistance explanation, to the observed preventive effect of removal of the pseudobranch on exophthalmia development (Dehadrai 1966). Moreover, it seems that the type of exophthalmia which Dehadrai observed was not the same as we observed. The present study and the studies by Rogers *et al.* (2008) and Hannah *et al.* (2008a) found pockets of gas behind the eye. In contrast, Dehadrai (1966) more likely found an excess gas secretion into the eye, rather than gas accumulation behind it, causing the eye to swell. This makes the bloodborne gas hypothesis a more likely mechanism in Dehadrai's experiment, while the path of least resistance hypothesis is a more likely explanation for the observed secondary barotrauma in our study. Yet, the bloodborne hypothesis cannot be ruled out as the underlying mechanism for the observed secondary exophthalmia in our study. The pseudobranch receives oxygenated blood from the first gill arch and supplies the choroid rete (inside the eye) with blood (Wittenberg & Wittenberg 1974). The choroid rete generates a high oxygen tension that allows diffusion to meet the vigorous oxygen demand of the avascular retina (Wittenberg & Wittenberg 1974). Ferter *et al.* (2015) observed gas bubbles in the venous blood stream of cod that were decompressed from deeper water and suffered from barotrauma, and one of our cod in the present study died from gas bubbles obstructing the blood flow. These gas bubbles might partly dissolve in the blood and lead to supersaturated blood in surviving fish. If this could lead to post-barotrauma supersaturation of arterial blood, exsolution in itself or high retinal tensions could theoretically lead to excess gas release in the choroid rete and cause secondary exophthalmia. Gas emboli may also form as a result of lowered gas solubility when the pH is lowered due to an increase in lactate and carbon dioxide build-up

(Parker *et al.* 2006). This can be caused by stress during capture (Stephens *et al.* 2001) and may affect the eye in particular due to the high retinal tensions. Hence, removal of the pseudobranch will cut the blood supply to the choroid gland and prevent secondary exophthalmia resulting from bloodborne gases.

In our study, the smaller fish (360–590 g) seemed to be more prone to develop exophthalmia than the larger fish. Similarly, Dehadrai (1966) studied cod in the range of 150–350 g, with high occurrences. However, a more focused experiment is needed to elucidate the role of size in interaction with capture depth and removal of the pseudobranch, in susceptibility to develop exophthalmia. In this context, careful consideration of mixing size groups should also be taken into consideration as one incidence of predation was observed.

Exophthalmia was not the only eye pathology observed. Fish no. 13 had an abrasion injury (not observed on day 0) that probably led to an opaque cornea and finally to loss of the eye, and this condition should therefore probably not be attributed to barotrauma alone. Fish no. 15 (Fig. 4) had ocular emphysema and probable buphthalmia in addition to exophthalmia. In this case, a link to the exophthalmic condition is apparent for ocular emphysema, although our data do not allow us to draw firm conclusions regarding the origin of gas. At the termination of our experiment, gas was only verified by registering bubbles. In future studies, both gas and fluid composition should be determined at the same time intervals post-decompression as using radiography and photography, which may shed light on the mechanisms behind the accumulation.

Our results have implications for a wide range of contexts in which cod are rapidly brought to the surface beyond their physiological ability to resorb gas (normally 40% pressure reduction from acclimation pressure; Arnold & Greer Walker 1992; Korsøen *et al.* 2010). Knowledge of capture stressors and their effects on survival and welfare are, for example, vital in assessing the fate of fish that escape from fishing gear (Suuronen, Lehtonen & Jounela 2005), are discarded (Davis 2002; Arlinghaus *et al.* 2007) or are kept alive for CBA or experimental purposes (Ottolenghi *et al.* 2004; Suuronen & Erickson 2010; Diggles *et al.* 2011; Midling *et al.* 2012). Particular attention should be paid to exophthalmia in cod CBA, where fish

are sorted immediately after capture and during transfer into 10-metre-deep net pens 1–4 days after capture, where they may be stored for up to 6 weeks. The concern is that secondary exophthalmia triggered by barotrauma may not yet be manifest at sorting, and fish predisposed to this condition are put into aquaculture. Hence, research on exophthalmia development in cod put into CBA is warranted in order to ensure good fish welfare.

Our experimental design did not permit us to test whether secondary exophthalmia triggered by barotrauma is a phenomenon that is specific to shallow-depth storage, or whether it also occurs in cod that have either been stored in deeper cages, manage to escape from fishing gear or are released at sea. Cod that escape or are released initially perform an ‘escape dive’ (Van Der Kooij *et al.* 2007) and though some return to a shallower depth, most descend to depths that are greater than under laboratory or CBA conditions (Ferter *et al.* 2015). Visual signs of exophthalmia have been shown to be reversible when fish are recompressed to their capture depth (Hannah & Matteson 2007; Jarvis & Lowe 2008; Rogers, Lowe & Fernández-Juricic 2011), although to the best of our knowledge, such cases been associated with acute rather than secondary exophthalmia. Thus, long-term effects of barotrauma on cod that return to capture depth should be studied, in view of the high escape rates in trawl fisheries (Suuronen *et al.* 2005) and high release rates for cod in recreational fisheries (Ferter *et al.* 2013a; Ferter *et al.* 2013b).

In conclusion, the main finding of this study is that barotrauma can trigger development of secondary exophthalmia in cod, measurable as an increase in overall eye protrusion, and first occurring 9 days after decompression, due to an accumulation of gas in the orbita. The origin of the gas is likely swim bladder gas taking the route of least resistance to the orbit. Further research should focus on how fish size in relation to capture depth affects exophthalmia development, and whether cod put into aquaculture are prone to the development of secondary exophthalmia.

Acknowledgements

Funding for this project was provided by the Institute of Marine Research. Further funding was provided by the tourist fishing project

(‘Kartlegging av turistfiske’) to K. Ferter through the Coastal Zone Ecosystem Program at the Institute of Marine Research. The authors are especially thankful to Britt Sværen Daae and Tone Vågseth for their assistance during the radiology experiments. The authors would also like to thank Richard S. Brown and an anonymous reviewer for providing constructive feedback on an earlier version of this manuscript.

References

- Arlinghaus R., Cooke S.J., Lyman J., Policansky D., Schwab A., Suski C., Sutton S.G. & Thorstad E.B. (2007) Understanding the complexity of catch-and-release in recreational fishing: an integrative synthesis of global knowledge from historical, ethical, social, and biological perspectives. *Reviews in Fisheries Science* **15**, 75–167.
- Arnold G.P. & Greer Walker M. (1992) Vertical movements of cod (*Gadus morhua* L.) in the open sea and the hydrostatic function of the swimbladder. *ICES Journal of Marine Science* **49**, 357–372.
- Bergstad O.A. (1991) Distribution and trophic ecology of some gadoid fish of the Norwegian deep: 1. Accounts of individual species. *Sarsia* **75**, 269–313.
- Brown R.S., Pflugrath B.D., Colotelo A.H., Brauner C.J., Carlson T.J., Deng Z.D. & Seaburg A.G. (2012) Pathways of barotrauma in juvenile salmonids exposed to simulated hydroturbine passage: Boyle’s law vs Henry’s law. *Fisheries Research* **121–122**, 43–50.
- Davis M.W. (2002) Key principles for understanding fish bycatch discard mortality. *Canadian Journal of Fisheries and Aquatic Sciences* **59**, 1834–1843.
- Dehadrai P.V. (1966) Mechanism of Gaseous Exophthalmia in the Atlantic Cod, *Gadus morhua* L. *Journal of the Fisheries Research Board of Canada* **23**, 909–914.
- Diggles B.K., Cooke S.J., Rose J.D. & Sawynok W. (2011) Ecology and welfare of aquatic animals in wild capture fisheries. *Reviews in Fish Biology and Fisheries* **21**, 739–765.
- Dukes T.W. (1975) Ophthalmic pathology of fishes. In: *The Pathology of Fishes*, pp. 383–398. University of Wisconsin Press, WI, USA.
- Ferter K., Borch T., Kolding J. & Vølstad J.H. (2013a) Angler behaviour and implications for management - catch-and-release among marine angling tourists in Norway. *Fisheries Management and Ecology* **20**, 137–147.
- Ferter K., Weltersbach M.S., Strehlow H.V., Vølstad J.H., Alós J., Arlinghaus R., Armstrong M., Dorow M., De Graaf M., Van Der Hammen T., Hyder K., Levrel H., Paulrud A., Radtke K., Rocklin D., Sparrevohn C.R. & Veiga P. (2013b) Unexpectedly high catch-and-release rates in European marine recreational fisheries: implications for science and management. *ICES Journal of Marine Science: Journal du Conseil* **70**, 1319–1329.

- Ferter K., Weltersbach M.S., Humborstad O.-B., Fjellidal P.G., Sambraus F., Strehlow H.V. & Vølstad J.H. (2015) Dive to survive: effects of capture depth on barotrauma and post-release survival of Atlantic cod (*Gadus morhua*) in recreational fisheries. *ICES Journal of Marine Science: Journal du Conseil* **72**, 2467–2481.
- Grahn B.H., Sangster C., Breaux C., Stephen C. & Sandmeyer L. (2007) Case report: clinical and pathologic manifestations of gas bubble disease in captive fish. *Journal of Exotic Pet Medicine* **16**, 104–112.
- Gunnarsli K.S., Toften H. & Mortensen A. (2008) Effects of nitrogen gas supersaturation on growth and survival in juvenile Atlantic cod (*Gadus morhua* L.). *Aquaculture* **283**, 175–179.
- Hannah R.W. & Matteson K.M. (2007) Behavior of nine species of Pacific rockfish after hook-and-line capture, recompression, and release. *Transactions of the American Fisheries Society* **136**, 24–33.
- Hannah R.W., Rankin P.S., Penny A.N. & Parker S.J. (2008a) Physical model of the development of external signs of barotrauma in Pacific rockfish. *Aquatic Biology* **3**, 291–296.
- Hannah R.W., Parker S.J. & Matteson K.M. (2008b) Escaping the surface: the effect of capture depth on submergence success of surface-released Pacific rockfish. *North American Journal of Fisheries Management* **28**, 694–700.
- Humborstad O.-B. & Mangor-Jensen A. (2013) Buoyancy adjustment after swimbladder puncture in cod *Gadus morhua*: an experimental study on the effect of rapid decompression in capture-based aquaculture. *Marine Biology Research* **9**, 383–393.
- Jarvis E.T. & Lowe C.G. (2008) The effects of barotrauma on the catch-and-release survival of southern California nearshore and shelf rockfish (Scorpaenidae, *Sebastes* spp.). *Canadian Journal of Fisheries and Aquatic Sciences* **65**, 1286–1296.
- Korsoen Ø.J., Dempster T., Fosseidengen J.E., Fernö A., Heegaard E. & Kristiansen T.S. (2010) Behavioural responses to pressure changes in cultured Atlantic cod (*Gadus morhua*): defining practical limits for submerging and lifting sea-cages. *Aquaculture* **308**, 106–115.
- Midling K.Ø., Koren C., Humborstad O.-B. & Sæther B.-S. (2012) Swimbladder healing in Atlantic cod (*Gadus morhua*), after decompression and rupture in capture-based aquaculture. *Marine Biology Research* **8**, 373–379.
- Moran D., Tubbs L. & Støttrup J.G. (2012) Chronic CO₂ exposure markedly increases the incidence of cataracts in juvenile Atlantic cod *Gadus morhua* L. *Aquaculture* **364–365**, 212–216.
- Ottolenghi F., Silvestri C., Giordano P., Lovatelli A. & New M.B. (2004) *Capture-based Aquaculture: The Fattening of Eels, Groupers, Tunas and Yellowtails*. FAO, Rome, Italy.
- Parker S.J., McElderry H.I., Rankin P.S. & Hannah R.W. (2006) Buoyancy regulation and barotrauma in two species of nearshore rockfish. *Transactions of the American Fisheries Society* **135**, 1213–1223.
- Parrish F.A. & Moffitt R.B. (1992) Subsurface fish handling to limit decompression effects on deepwater species. *Marine Fisheries Review* **54**, 29–32.
- Rogers B.L., Lowe C.G., Fernandez-Juricic E. & Frank L.R. (2008) Utilizing magnetic resonance imaging (MRI) to assess the effects of angling-induced barotrauma on rockfish (*Sebastes*). *Canadian Journal of Fisheries and Aquatic Sciences* **65**, 1245–1249.
- Rogers B.L., Lowe C.G. & Fernández-Juricic E. (2011) Recovery of visual performance in rosy rockfish (*Sebastes rosenblatti*) following exophthalmia resulting from barotrauma. *Fisheries Research* **112**, 1–7.
- Rummer J.L. & Bennett W.A. (2005) Physiological effects of swim bladder overexpansion and catastrophic decompression on Red Snapper. *Transactions of the American Fisheries Society* **134**, 1457–1470.
- Stephens F., Cleary J., Jenkins G., Jones B., Raidal S. & Thomas J. (2001) Pathogenesis and epidemiology of spontaneous exophthalmos in the West Australian dhufish, *Glaucosoma hebraicum* Richardson. *Journal of Fish Diseases* **24**, 515–522.
- Suuronen P. & Erickson D.L. (2010) Mortality of animals that escape fishing gears or are discarded after capture: approaches to reduce mortality. *Behavior of Marine Fishes: Capture Processes and Conservation Challenges* **26**, 5–293.
- Suuronen P., Lehtonen E. & Jounela P. (2005) Escape mortality of trawl caught Baltic cod (*Gadus morhua*) — the effect of water temperature, fish size and codend catch. *Fisheries Research* **71**, 151–163.
- Tytler P. & Blaxter J. (1973) Adaptation by cod and saithe to pressure changes. *Netherlands Journal of Sea Research* **7**, 31–45.
- Van Der Kooij J., Righton D., Strand E., Michalsen K., Thorsteinsson V., Svedäng H., Neat F.C. & Neuenfeldt S. (2007) Life under pressure: insights from electronic data-storage tags into cod swimbladder function. *ICES Journal of Marine Science* **64**, 1293–1301.
- Wittenberg J.B. & Wittenberg B.A. (1974) The choroid rete mirabile of the fish eye. I. Oxygen secretion and structure: comparison with the swimbladder rete mirabile. *The Biological Bulletin* **146**, 116–136.

Received: 21 December 2015

Revision received: 26 February 2016

Accepted: 26 February 2016